

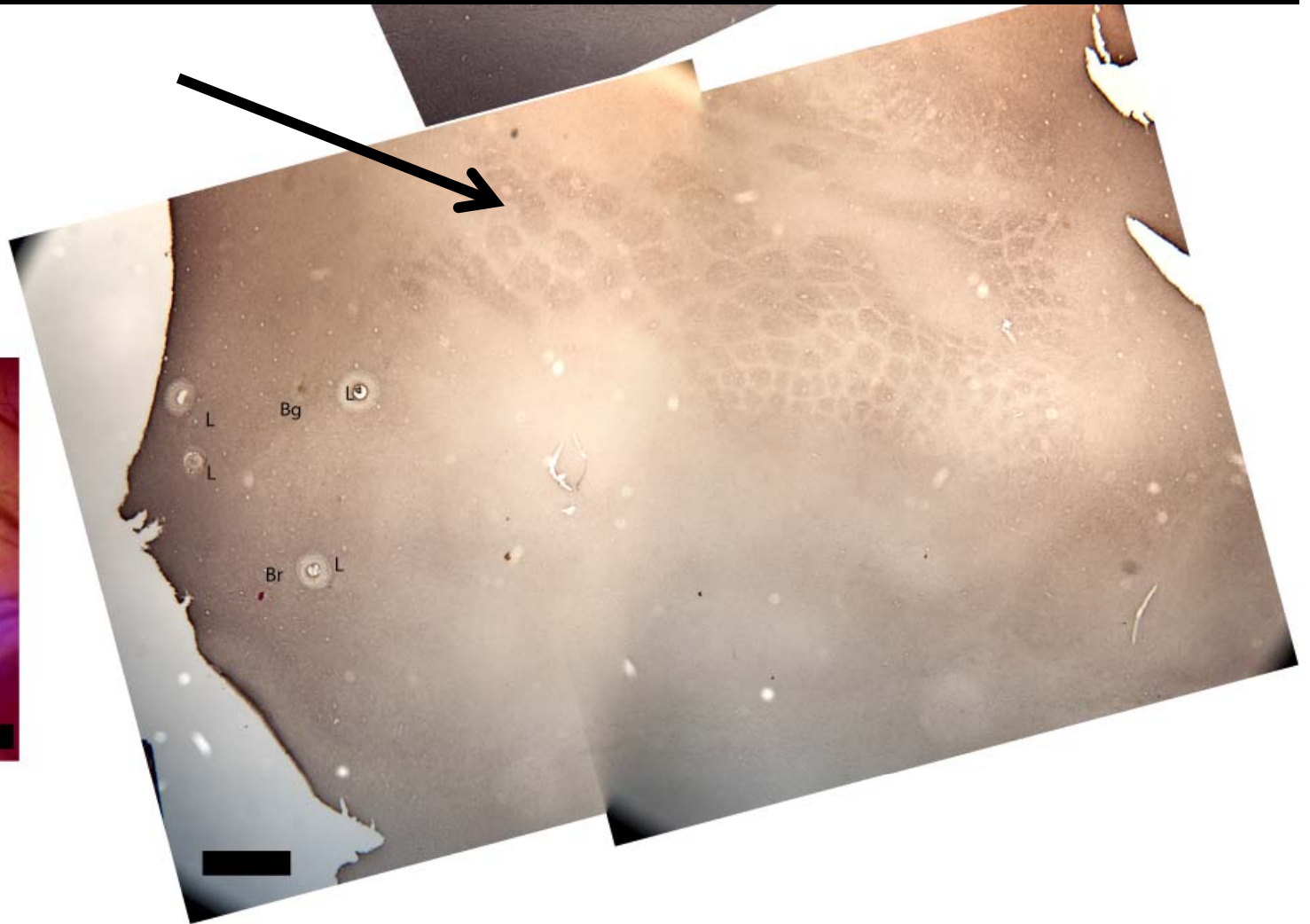
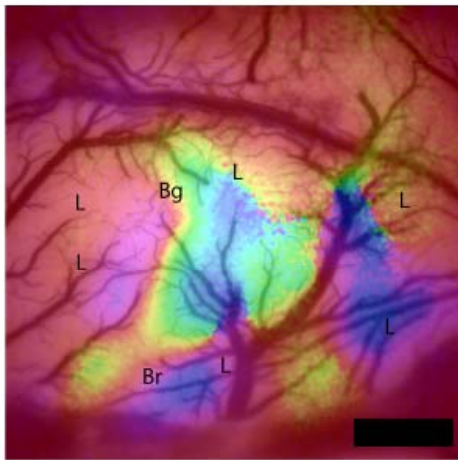
---

Neocortex 2 – 9-29-2011



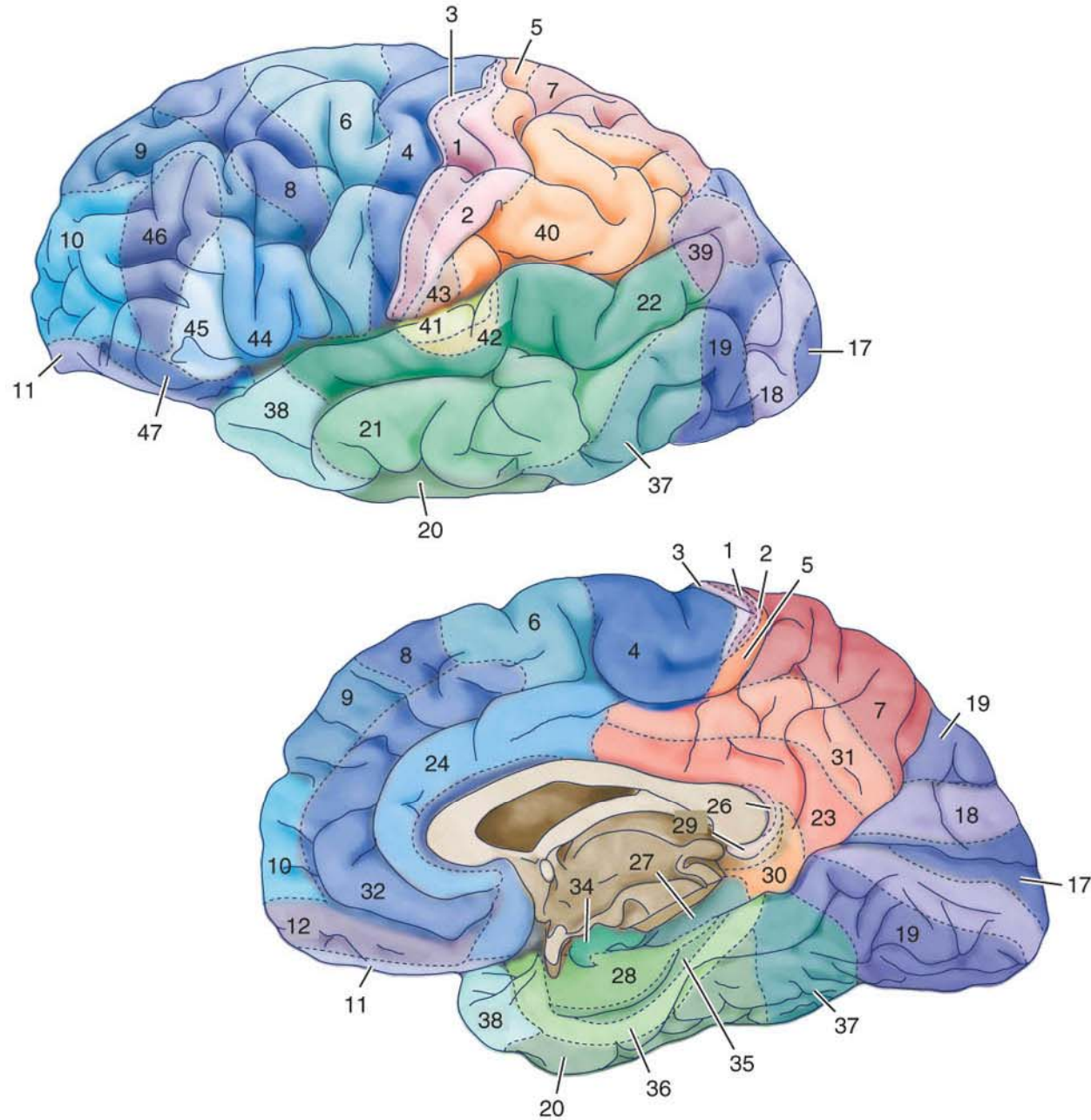
**MEDS 5384**

# Barrel cortex in rat



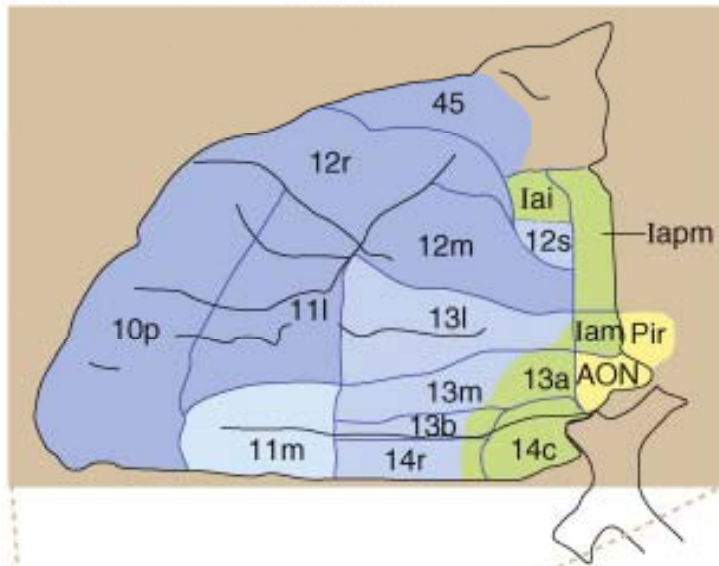
## 25.2 The structure of the human neocortex, including the association cortices. (Part 2)

(B)



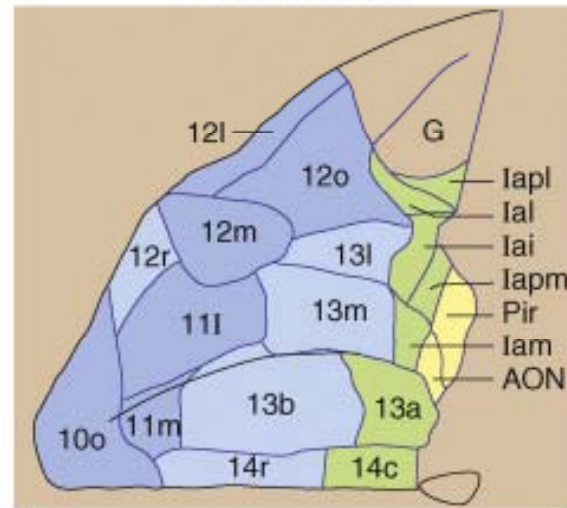
(a) (i)

Human



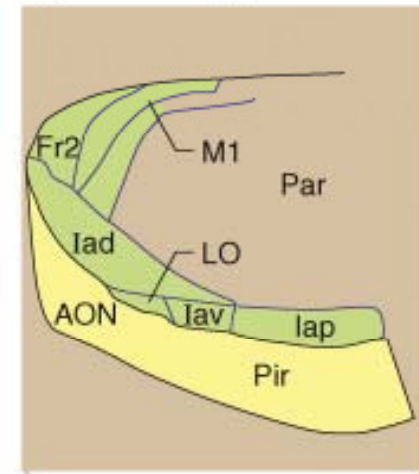
(ii)

Macaque monkey

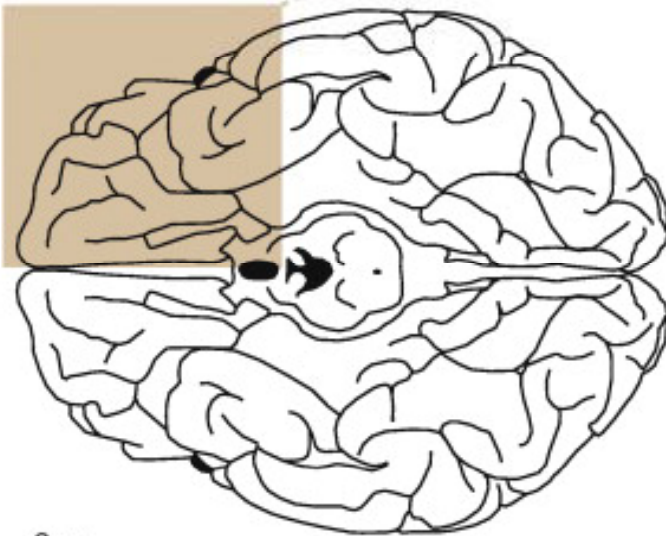


(iii)

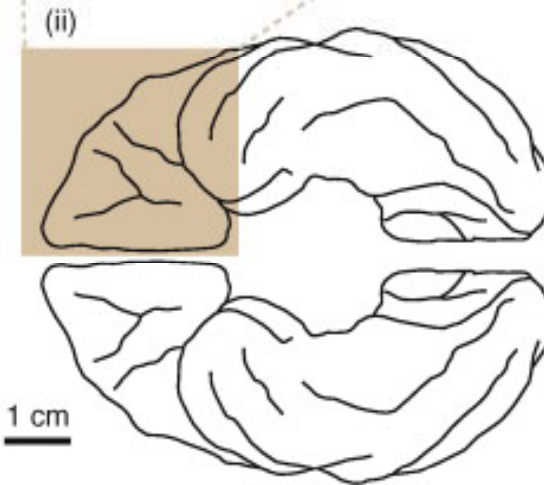
Rat



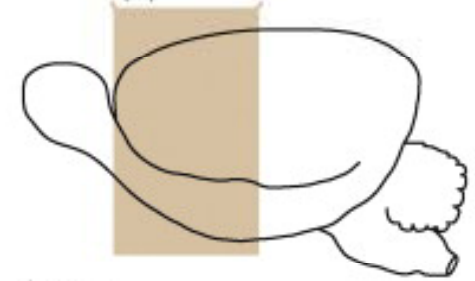
(b) (i)



(ii)



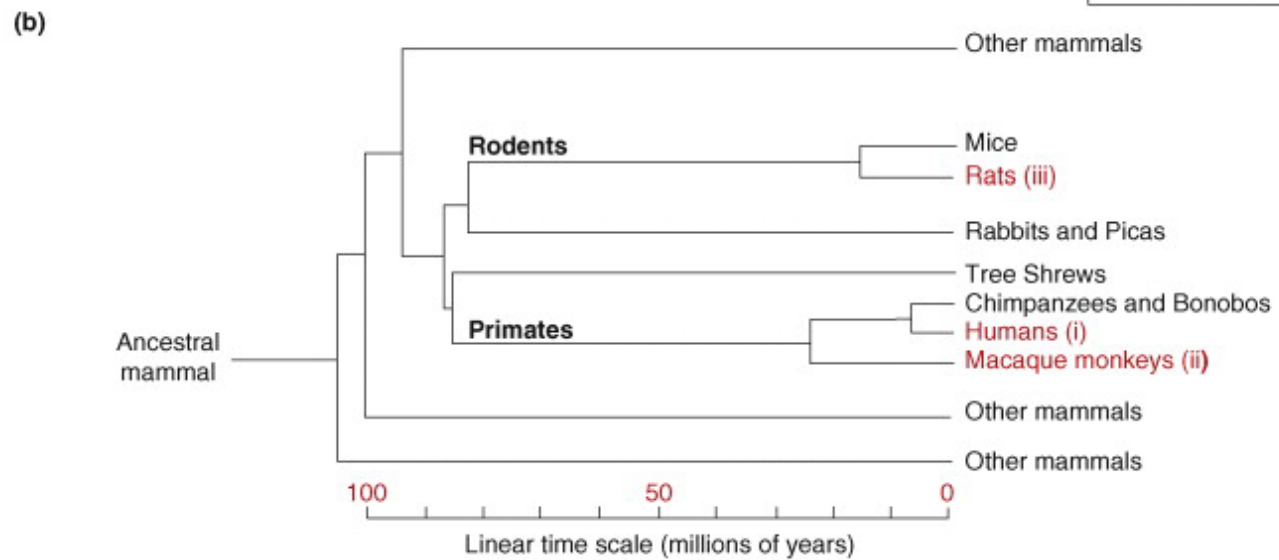
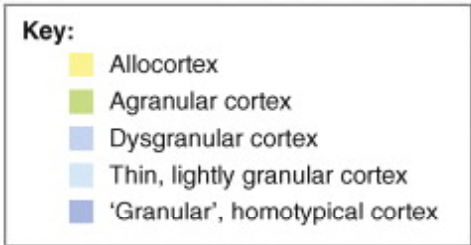
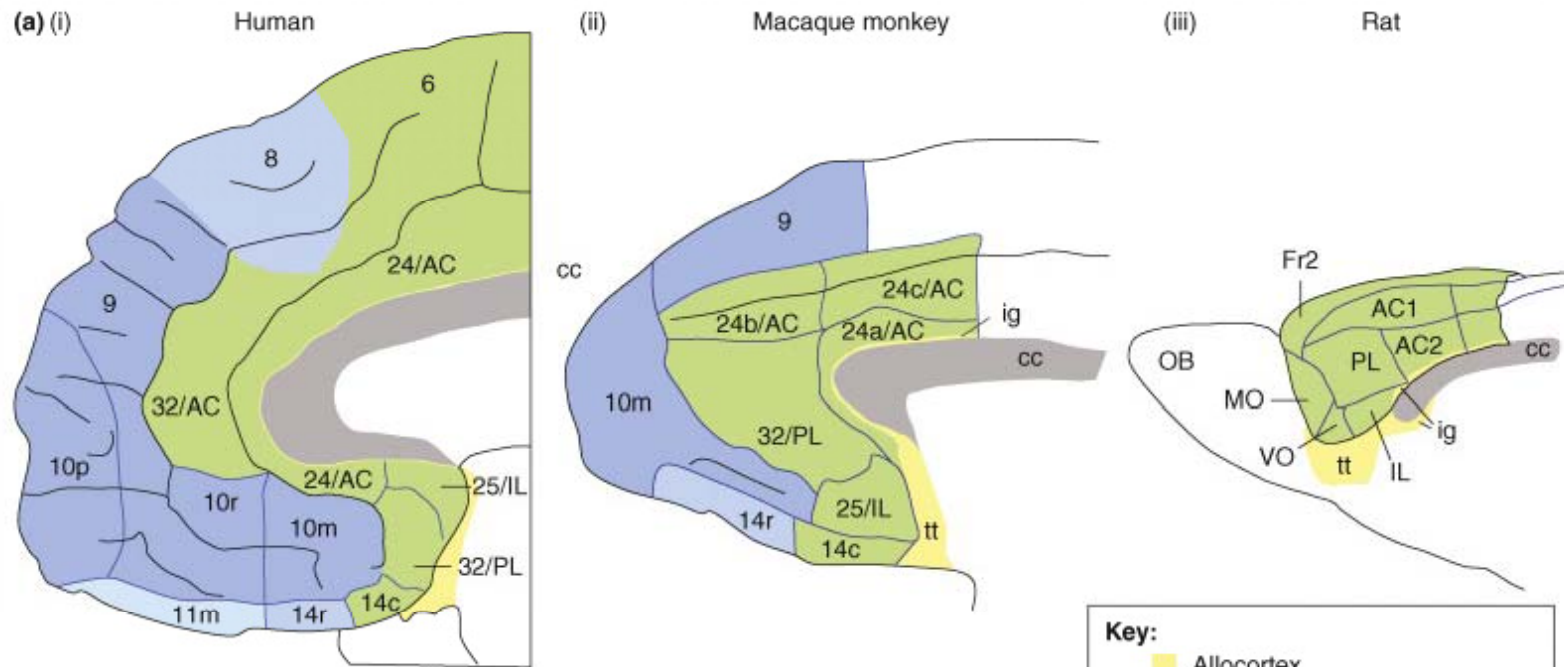
(iii)



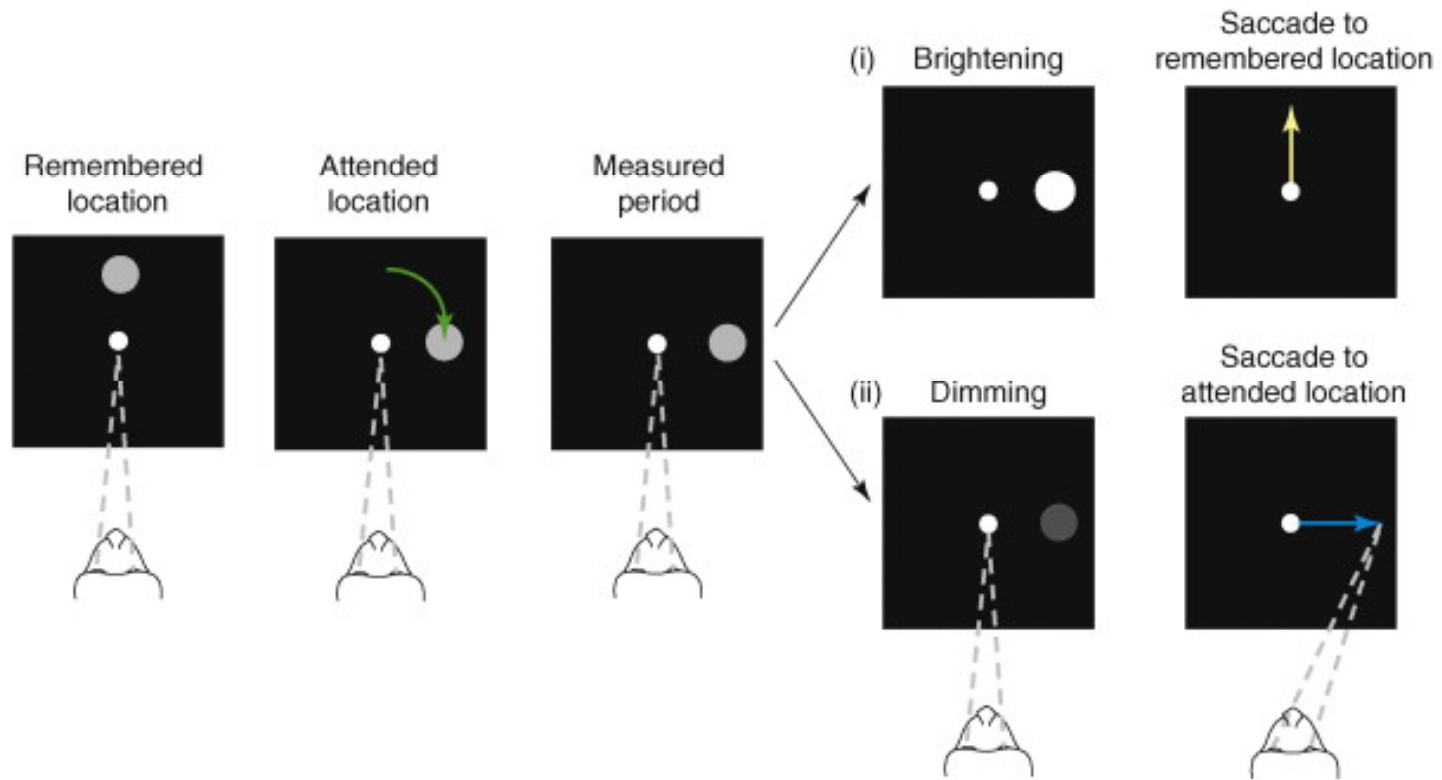
Key:

- Allocortex
- Agranular cortex
- Dysgranular cortex
- Thin, lightly granular cortex
- 'Granular', homotypical cortex

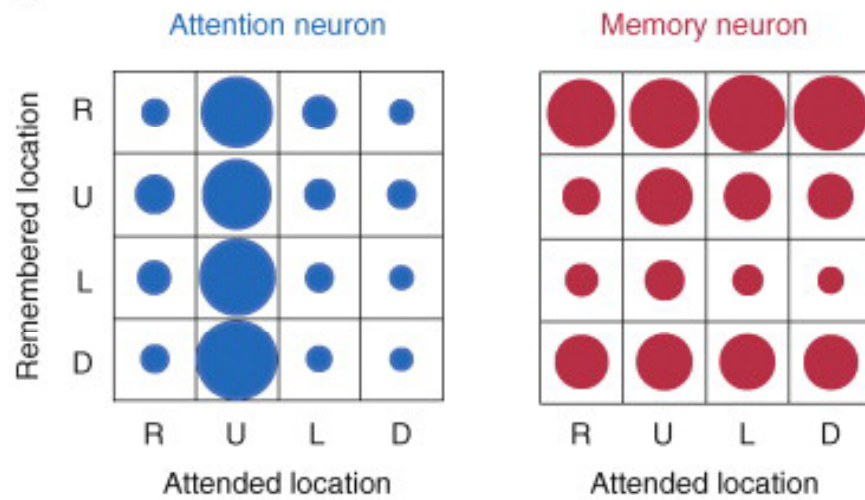




(a)



(b)



(c)

